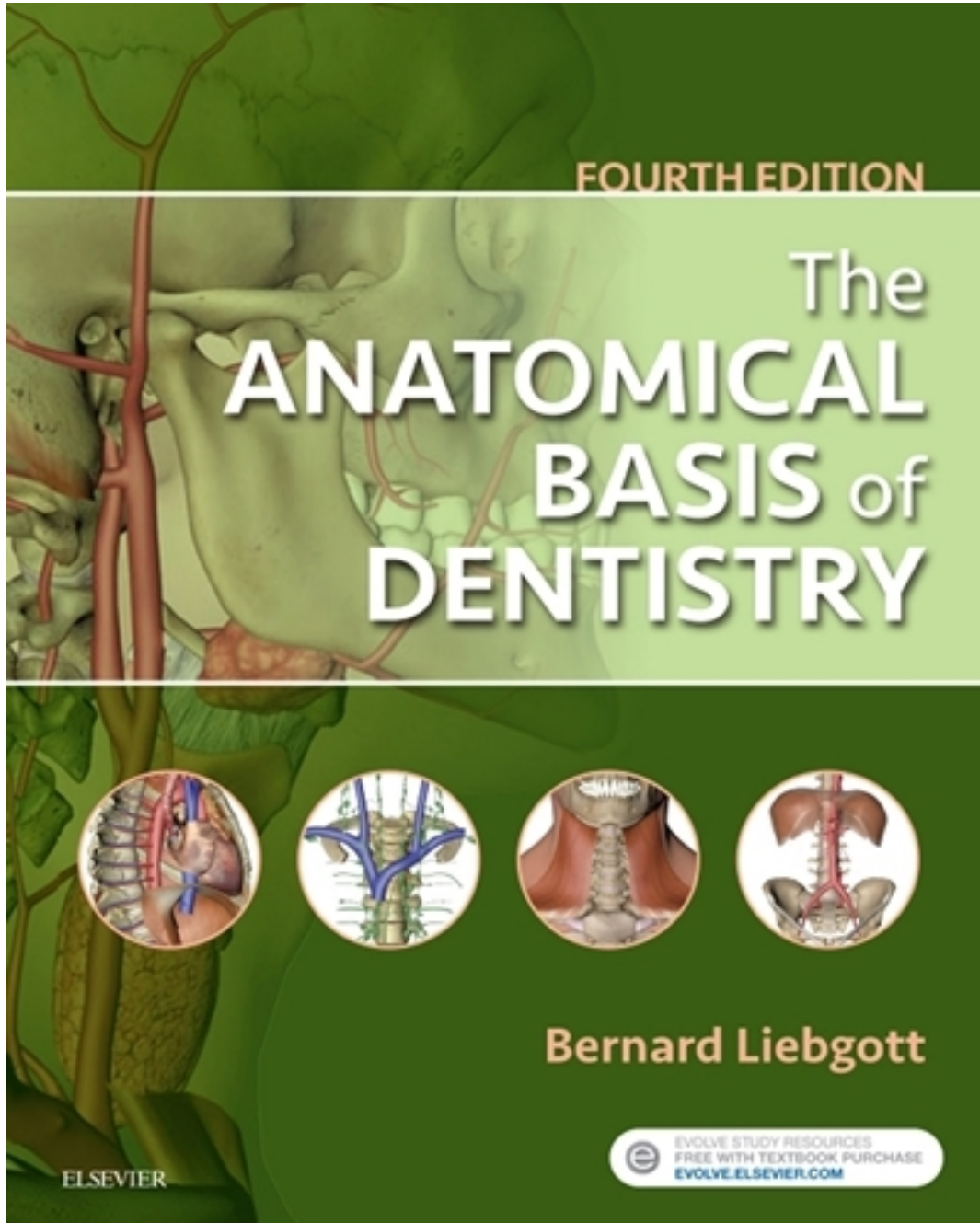


Test Bank for Anatomical Basis of Dentistry 4th Edition by Liebgott

[CLICK HERE TO ACCESS COMPLETE Test Bank](#)



Test Bank

Chapter 02: The Back

Liebgoth: The Anatomical Basis of Dentistry, 4th Edition

MULTIPLE CHOICE

1. The posterior surface of the skull is the _____.
- dens*
 - occiput*
 - odontoid process*
 - transverse process*
 - coccyx*

ANS: B

Occiput. The posterior surface of the skull is convex and is commonly called the *occiput*.

2. How many vertebrae are in the spine?
- 12
 - 16
 - 21
 - 33
 - 42

ANS: D

33. The vertebral column, or spine, has 33 vertebrae: 7 cervical, 12 thoracic, 5 lumbar, 5 sacral (fused), and 4 coccygeal (fused).

3. There are ____ cervical vertebrae in the spine.
- 2
 - 3
 - 4
 - 6
 - 7

ANS: E

7. There are 7 cervical vertebrae in the spine.

4. The vertebral foramen, which houses the spinal cord, is formed by the _____.
- occiput and nuchal line
 - inion and occiput
 - vertebral arch and body
 - vertebral notches
 - transverse process and spinous process

ANS: C

Vertebral arch and body. The vertebral arch and body form the vertebral foramen, which encloses and protects the spinal cord.

5. The arches in an articulated vertebral column form the _____, which houses the entire spinal cord.
- vertebral canal

- b. intervertebral foramina
- c. transverse process
- d. spinous process
- e. transverse foramen

ANS: A

Vertebral canal. The arches in an articulated vertebral column form the vertebral canal, which houses the spinal cord.

6. The transverse foramen in the cervical vertebrae provides a conduit for which of the following?
- a. Spinal cord
 - b. Occiput
 - c. Posterior tubercle
 - d. Vertebral artery and vein
 - e. Dens

ANS: D

Vertebral artery and vein. Cervical vertebrae exhibit a transverse foramen, a hole through the transverse processes to transmit the vertebral artery and vein.

7. Which characteristic of the thoracic vertebrae distinguishes them from other vertebrae?
- a. The spinous process is short and thick.
 - b. There are fewer vertebrae than in the other components of the spinal column.
 - c. There is no body in the thoracic vertebrae.
 - d. The body is heart-shaped.
 - e. The body is rectangular.

ANS: D

The body is heart-shaped. The 12 thoracic vertebrae exhibit features that distinguish them from other vertebrae: (1) the spinous process is long and slender; (2) the body has an articulating facet for the head of a rib; (3) the transverse process has an articulating facet for the tubercle of a rib; and (4) the body is heart-shaped.

8. Which vertebrae are long and slender, have facets for connection to the ribs, and are heart-shaped?
- a. Lumbar
 - b. Thoracic
 - c. Cervical
 - d. Sacral
 - e. Coccygeal

ANS: B

Thoracic. The 12 thoracic vertebrae exhibit features that distinguish them from other vertebrae: (1) the spinous process is long and slender; (2) the body has an articulating facet for the head of a rib; (3) the transverse process has an articulating facet for the tubercle of a rib; and (4) the body is heart-shaped.

9. Which type of vertebrae has no facets for ribs; is relatively massive, with bean-shaped bodies; and has spinous processes that are not bifid but square?
- a. Lumbar

- b. Thoracic
- c. Cervical
- d. Sacral
- e. Coccygeal

ANS: A

Lumbar. Three features distinguish the lumbar vertebrae: (1) they are relatively massive, with bean-shaped bodies; (2) they have no facets for ribs; and (3) the spinous processes are neither bifid nor slender but square.

10. The normal curvatures in the cervical and lumbosacral regions of the human spine are formed by _____.
- a. changes in the shape of vertebrae as a child grows
 - b. maturing of muscle through the life span
 - c. removal of vertebrae
 - d. action of the thyroid gland
 - e. intervertebral discs of the curved regions assuming a wedge shape

ANS: E

Wedge shape of intervertebral discs. In the neonate, the fetal, or primary, curvature of the vertebral column is present. A convex cervical secondary curvature appears in the cervical area when the child learns to hold the head erect. When the child learns to walk, a secondary curve appears in the lumbosacral region. The curvatures are formed by the intervertebral discs of the curved regions assuming a wedge shape.

11. An intervertebral disc in the spinal column is composed of _____.
- a. hyaline cartilage
 - b. fibrocartilaginous fibers (annulus fibrosus) and pulpal nucleus
 - c. longitudinal ligaments and cartilage
 - d. transverse foramina and ligaments
 - e. none of the above

ANS: B

Fibrocartilaginous fibers. Between two vertebrae is a disc consisting of concentric layers of fibrocartilaginous fibers (annulus fibrosus) surrounding a nucleus of fibrogelatinous material (pulpal nucleus).

12. Nerve roots descend past the termination of the spinal cord at L2 and resemble a horse's tail. The term for these nerve roots is _____.
- a. *anulus fibrosis*
 - b. *syndesmosis*
 - c. *intergluteal sulcus*
 - d. *cauda equina*
 - e. *lumbosacral cauda*

ANS: D

Cauda equina. The nerve roots that descend past the spinal cord at L2 are termed the *cauda equina*.

13. The fine membrane that covers the spinal cord and forms the denticulate ligament, which anchors the spinal cord to the vertebral canal, is the _____.

- a. pia mater
- b. arachnoid mater
- c. dura mater
- d. filum terminale
- e. membranous layer

ANS: A

Pia mater. The pia mater is a fine membrane that covers the spinal cord intimately, following each fissure and groove. It covers the spinal rootlets and extends laterally between the rootlets as a scalloped denticulate ligament. Dura mater is the outermost layer of the meninges.

14. The tough, heavy durable membrane that is the outer layer of membranes covering the spinal cord is the _____.
- a. pia mater
 - b. arachnoid mater
 - c. dura mater
 - d. filum terminale
 - e. membranous layer

ANS: C

Dura mater. The dura mater is the outermost layer of the meninges that cover the spinal cord and consists of a tough, heavy, and durable membrane. Pia mater is the fine membrane that covers the spinal cord intimately.

15. _____ is a potentially lethal inflammation of the brain or spinal cord caused by bacterial or viral infections that spread hematogenously in the cerebrospinal fluid (CSF).
- a. Synovitis
 - b. Meningitis
 - c. Kyphosis
 - d. Scoliosis
 - e. Lordosis

ANS: B

Meningitis. Meningitis is a potentially lethal inflammation of the brain or spinal cord meninges caused by bacterial or viral infections that spread hematogenously in the CSF. Kyphosis, scoliosis, and lordosis are abnormal curvatures of the spine.