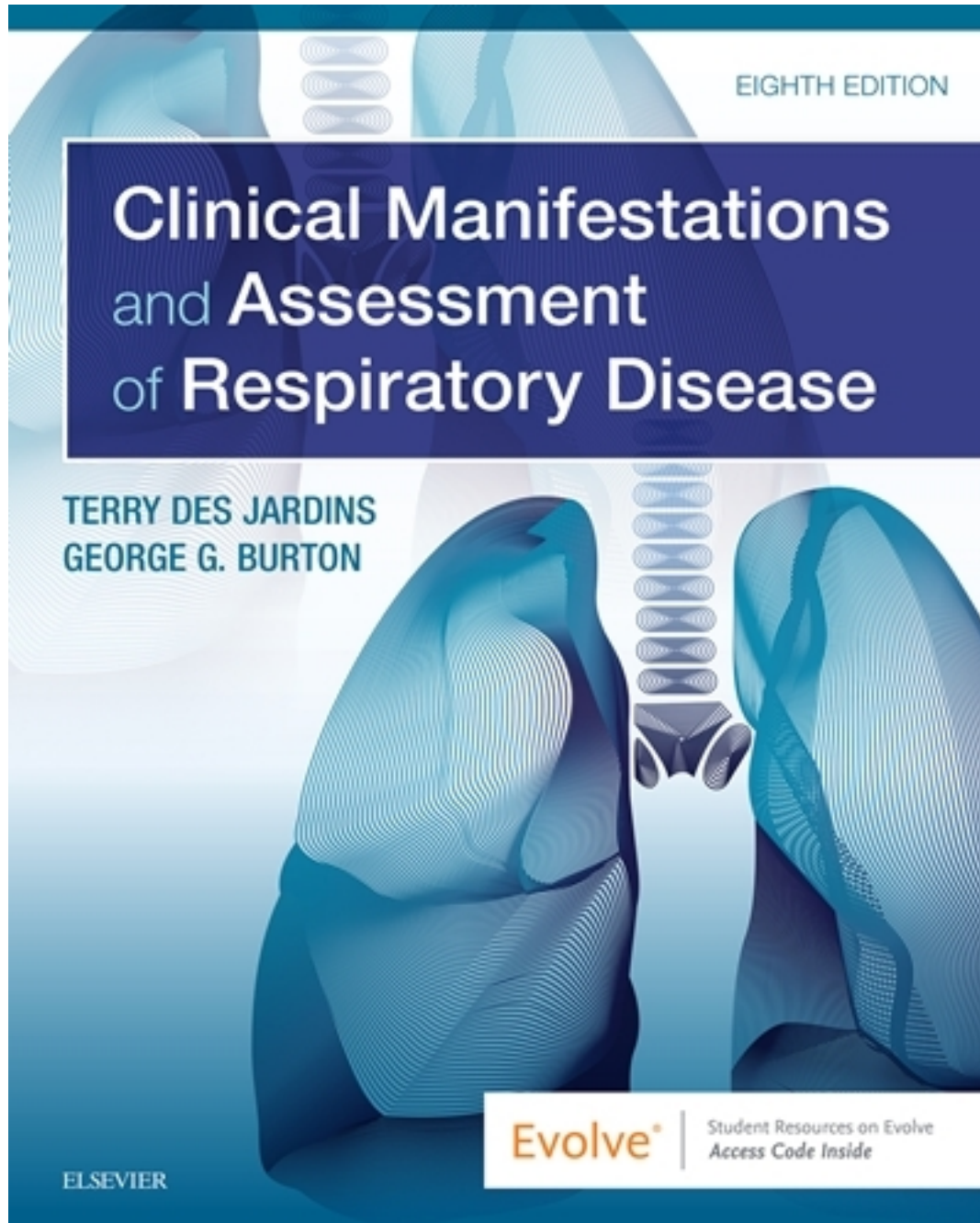


Test Bank for Clinical Manifestations and Assessment of Respiratory Disease 8th Edition by Jardins

[CLICK HERE TO ACCESS COMPLETE Test Bank](#)



Test Bank

Chapter 02: The Physical Examination

Des Jardins: Clinical Manifestations and Assessment of Respiratory Disease, 8th Edition

MULTIPLE CHOICE

1. When would induced hypothermia be indicated?
 - a. During brain surgery
 - b. During bowel surgery
 - c. To break a fever
 - d. To treat carbon monoxide poisoning

ANS: A

Induced hypothermia may involve only a portion of the body or the whole body. Induced hypothermia is often indicated before certain surgeries, such as heart or brain surgery, or after return of spontaneous circulation after a cardiac arrest.

2. A 50-year-old patient has a heart rate by palpation of 120 bpm. How should this be interpreted?
 - a. Within the normal range for an adult
 - b. An error since a stethoscope was not used
 - c. Bradycardia
 - d. Tachycardia

ANS: D

In an adult, a heart rate of greater than 100/minute is considered to be tachycardia. A heart rate of less than 60/minute in an adult is considered to be bradycardia. Palpation and auscultation are both acceptable to check heart rate.

3. Tachypnea may be the result of:
 1. hypoxemia.
 2. hypothermia.
 3. fever.
 4. sedation.
 - a. 2, 4
 - b. 1, 3
 - c. 2, 3, 4
 - d. 1, 2, 3

ANS: B

Tachypnea may be the result of hypoxemia, fever, and other causes. Hypothermia and sedation will usually result in bradycardia.

4. A 50-year-old patient would be said to have hypotension when her:
 - a. blood pressure is 130/90 mm Hg.
 - b. blood pressure is 85/55 mm Hg.
 - c. heart rate is 55 bpm.
 - d. pulse pressure is 40 mm Hg.

ANS: B

Hypotension is said to be present when the patient's blood pressure falls below 90/60 mm Hg. A heart rate of 55 bpm would be bradycardia. Pulse pressure is normally about 40 mm Hg.

5. A dull percussion note would be heard in which of the following situations?

1. Atelectasis
 2. Pleural thickening
 3. Chronic obstructive pulmonary disease (COPD)
 4. Consolidation
- a. 1, 2
 - b. 3, 4
 - c. 2, 3, 4
 - d. 1, 2, 4

ANS: D

Because of hyperinflation, a patient with COPD would have a hyperresonant percussion note. All of the other listed options would result in a dull percussion note.

6. Coarse crackles are associated with:

1. inspiration typically.
 2. air passing through an airway intermittently occluded by mucus.
 3. bronchial asthma.
 4. expiration typically.
- a. 2, 4
 - b. 3, 4
 - c. 2, 3, 4
 - d. 1, 2, 3

ANS: A

Coarse crackles are associated with air passing through an airway intermittently occluded by mucus; they are more typically heard during inspiration, not expiration. Wheezes are an expiratory sound associated with bronchial asthma.

7. While assessing an unconscious patient, the respiratory therapist observes that the patient's breathing becomes progressively faster and deeper and then progressively becomes slower and shallower. After that, there is a period of apnea before the cycle begins again. This breathing pattern would be identified as:

- a. Cheyne-Stokes.
- b. Tachypnea.
- c. Kussmaul.
- d. Hyperventilation.

ANS: A

The abnormal breathing pattern called *Cheyne-Stokes* is identified by progressively faster and deeper breathing that then progressively becomes slower and shallower. After that there is a period of apnea before the cycle begins again. Tachypnea is rapid breathing. Kussmaul breathing is consistently fast and deep breathing. Hyperventilation is confirmed by a low carbon dioxide level.

8. Benefits of pursed-lip breathing include that it:

1. stabilizes airways.
 2. offsets air trapping on exhalation.
 3. generates a better gas mixing breathing pattern.
 4. increases the respiratory rate.
- a. 1
 - b. 2, 3
 - c. 1, 2, 3
 - d. 2, 3, 4

ANS: C

All of the listed options are benefits of pursed-lip breathing in a patient with an airway obstruction problem such as asthma or COPD.

9. A patient comes into the emergency department with a complaint of centrally located, constant chest pain. What is his most likely problem?
- a. Pleurisy
 - b. Myocardial ischemia
 - c. Pneumothorax
 - d. Fractured rib

ANS: B

Often a patient with myocardial ischemia will complain of centrally located, constant chest pain. The pain may also radiate down an arm or up the neck.

10. A patient with bronchiectasis has a productive cough. Which of the following should the respiratory therapist be evaluating about the patient's sputum?
1. Color
 2. Odor
 3. Frequency of cough
 4. Consistency
- a. 3
 - b. 1, 2
 - c. 3, 4
 - d. 1, 2, 4

ANS: D

The respiratory therapist should evaluate a patient's sputum for color, odor, amount, consistency, and any other significant factors. This could include time of greater or smaller amounts or a change in consistency after inhaling a mucolytic medication.

11. The respiratory therapist is monitoring the blood pressure of a patient in the emergency department and notes that the blood pressure is 15 mm Hg less on inspiration than on expiration. Which of the following would most likely result in this finding?
- a. The patient is hypovolemic.
 - b. The patient has a pulmonary embolism.
 - c. The patient is having a myocardial infarction.
 - d. The patient is having a severe exacerbation of asthma.

ANS: D

A change in blood pressure that is more than 10 mm Hg lower on inspiration than on expiration is known as *pulsus paradoxus*. This exaggerated waxing and waning of arterial blood pressure can be detected with a sphygmomanometer or, in severe cases, by palpating the pulse at the wrist or neck. Commonly associated with severe asthmatic episodes, pulsus paradoxus is believed to be caused by the major intrapleural pressure swings that occur during inspiration and expiration.

12. The respiratory therapist is examining a patient in the medical ward and notes that the trachea is deviated to the right. Which of the following may be causing the tracheal deviation to the right?
- A right-sided tension pneumothorax.
 - A right-sided pleural effusion.
 - A tumor mass on the right.
 - Atelectasis of the right upper lobe.

ANS: D

A number of abnormal pulmonary conditions can cause the trachea to deviate from its normal position. For example, a tension pneumothorax, pleural effusion, or tumor mass may push the trachea to the unaffected side (in this case to the left), whereas atelectasis pulls the trachea to the affected side (in this case to the right).

13. The respiratory therapist is performing palpation on a patient recently admitted to the medical ward. The therapist notes decreased tactile fremitus over the right lung. Which of the following could most likely be the cause for this physical examination finding?
- Right-sided atelectasis
 - Right-sided pneumothorax
 - Right-sided pleural effusion
 - Right-sided pleural tumor

ANS: A

Tactile fremitus decreases when anything obstructs the transmission of vibration. Such conditions include tumors or thickening of the pleural cavity, pleural effusion, and pneumothorax. Tactile fremitus increases in patients with atelectasis.

14. Moderate hypoxemia is indicated with an SpO₂ value between _____ and _____.
- 95%; 99%
 - 91%; 94%
 - 86%; 90%
 - 80%; 85%

ANS: C

In the adult, normal SpO₂ values range from 95% to 99%. SpO₂ values of 91% to 94% indicate mild hypoxemia. Mild hypoxemia warrants additional evaluation by the respiratory practitioner but does not usually require supplemental oxygen. SpO₂ readings of 86% to 90% indicate moderate hypoxemia. These patients often require supplemental oxygen. SpO₂ values of 85% or lower indicate severe hypoxemia and warrant immediate medical intervention, including the administration of oxygen, ventilatory support, or both.