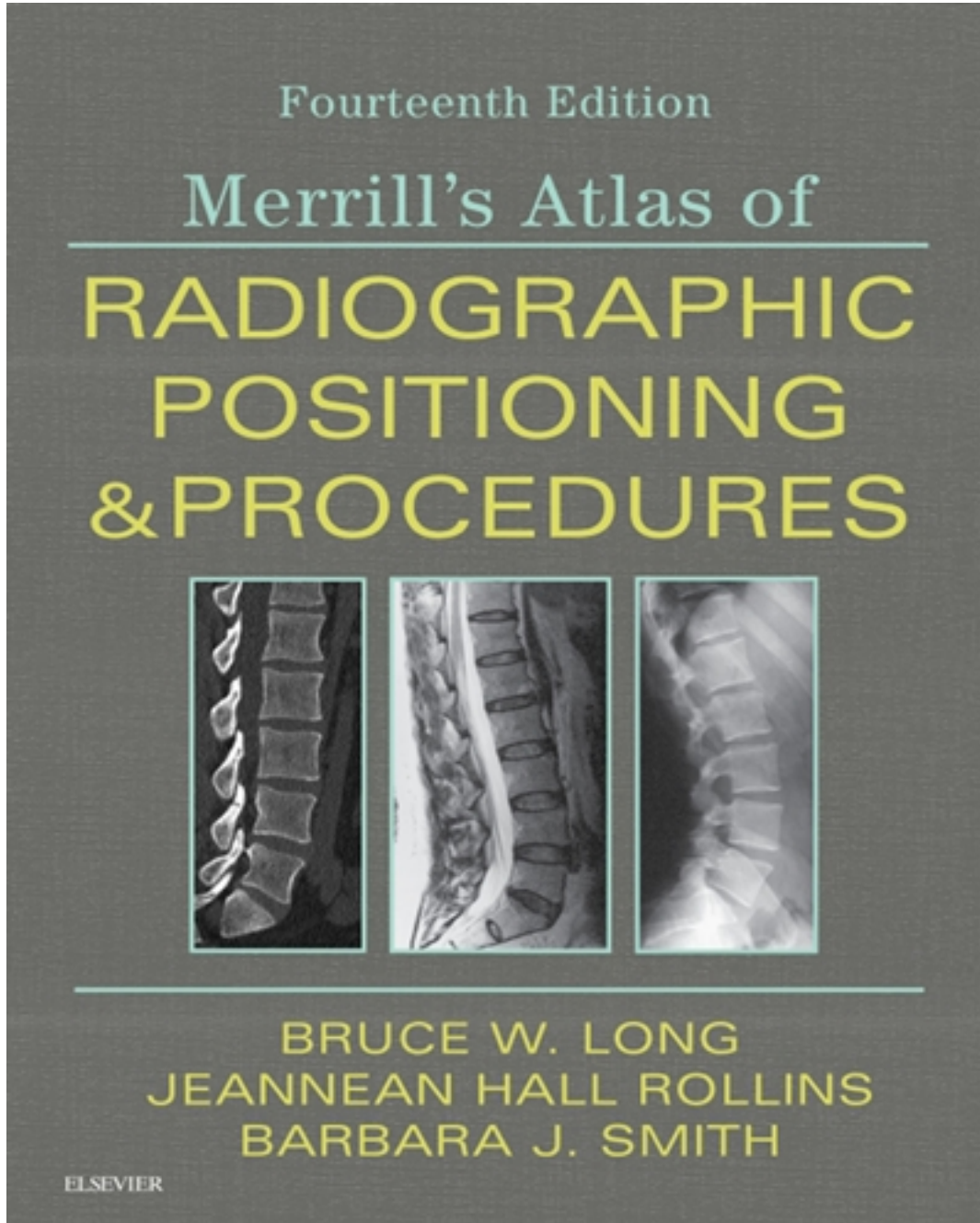


Test Bank for Merrill's Atlas of Radiographic Positioning and Procedures 14th Edition by Long

[CLICK HERE TO ACCESS COMPLETE Test Bank](#)



Test Bank

Chapter 02: General Anatomy and Radiographic Positioning Terminology
Long: Merrill's Atlas of Radiographic Positioning and Procedures, 14th Edition

MULTIPLE CHOICE

1. In the "anatomic position," the palms of the hands are facing:
 - a. backward.
 - b. forward.
 - c. up.
 - d. down.

ANS: B

2. A plane passing through the body parallel with the midsagittal plane is termed:
 - a. coronal.
 - b. sagittal.
 - c. axial.
 - d. oblique.

ANS: B

3. A plane passing vertically through the body from side to side is termed:
 - a. oblique.
 - b. sagittal.
 - c. coronal.
 - d. horizontal.

ANS: C

4. Any plane passing through the body at right angles to its longitudinal axis is termed:
 - a. coronal.
 - b. oblique.
 - c. sagittal.
 - d. horizontal.

ANS: D

5. All of the following are located in the thoracic cavity *except*:
 - a. trachea.
 - b. spleen.
 - c. lungs.
 - d. esophagus.

ANS: B

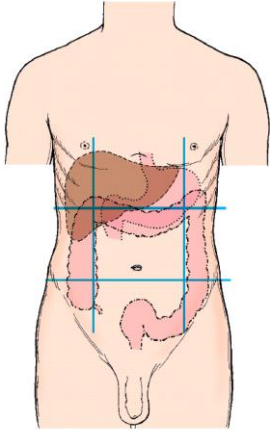
6. All of the following are located in the abdominal cavity *except*:
 - a. kidneys.
 - b. stomach.
 - c. rectum.
 - d. pancreas.

ANS: C

7. Into how many regions is the abdomen divided?
- a. Two
 - b. Four
 - c. Six
 - d. Nine

ANS: D

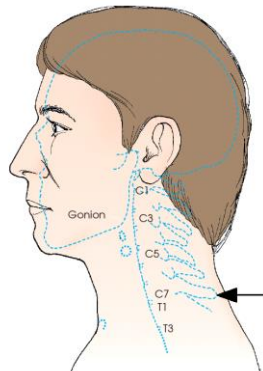
8. The lower, center region on this figure is termed the:



- a. epigastrium.
- b. lumbar.
- c. inguinal.
- d. hypogastrium.

ANS: D

9. The external landmark indicated by the arrow in this figure is the:



- a. mastoid tip.
- b. vertebra prominens.
- c. gonion.
- d. transverse process.

ANS: B

10. T9 and T10 are located at the level of the:
- a. sternal angle.
 - b. xiphoid process.

- c. jugular notch.
- d. vertebra prominens.

ANS: B

11. L4 and L5 are located at the level of the:
- a. costal margin.
 - b. superior iliac spine.
 - c. umbilicus.
 - d. superior aspect of the iliac crests.

ANS: D

12. S1 and S2 are located at the level of the:
- a. costal margin.
 - b. umbilicus.
 - c. superior aspect of the iliac crests.
 - d. anterior superior iliac spines (ASISs).

ANS: D

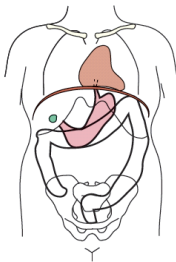
13. All of the following are types of body habitus, *except*:
- a. atrophic.
 - b. sthenic.
 - c. asthenic.
 - d. hypersthenic.

ANS: A

14. Approximately what percentage of the population has a sthenic body habitus?
- a. 5%
 - b. 10%
 - c. 35%
 - d. 50%

ANS: D

15. Which body habitus is shown in this figure?



- a. Hypersthenic
- b. Hyposthenic
- c. Asthenic
- d. Atrophic

ANS: A

16. The least-occurring body habitus is the:
- hyposthenic.
 - hypersthenic.
 - asthenic.
 - atrophic.

ANS: B

17. The adult skeleton is composed of how many bones?
- 185
 - 200
 - 206
 - 208

ANS: C

18. Bones are composed of an outer layer of compact bony tissue called the:
- compact bone.
 - periosteum.
 - spongy tissue.
 - medullary canal.

ANS: A

19. Long bones have a central cylindrical cavity called the:
- meniscus.
 - periosteum.
 - medullary cavity.
 - spongy tissue.

ANS: C

20. How many specific types of synovial joints are there?
- Three
 - Four
 - Five
 - Six

ANS: D

21. Some synovial joints contain synovial fluid-filled sacs outside the main joint cavity called:
- bursae.
 - menisci.
 - ligaments.
 - fibrous capsules.

ANS: A

22. How many saddle joints are there in the body?
- One
 - Two
 - Three
 - Four

ANS: A

23. Some synovial joints contain a thick cushioning pad of fibrocartilage called the:
- bursae.
 - meniscus.
 - cartilage.
 - fibrous capsule.

ANS: B

24. Which specific type of joint allows multiaxial movement?
- Pivot
 - Gliding
 - Ellipsoid
 - Ball and socket

ANS: D

25. After birth, a separate bone begins to develop at the *ends* of long bones. Each end is called the:
- diaphysis.
 - epiphysis.
 - epiphyseal line.
 - epiphyseal plate.

ANS: B

26. A rounded process at an articular extremity is called a:
- condyle.
 - malleolus.
 - tubercle.
 - styloid.

ANS: A

27. A hole in a bone for transmission of blood vessels and nerves is called a:
- groove.
 - foramen.
 - fissure.
 - facet.

ANS: B

28. A small, smooth-surfaced process for articulation of bones is called a:
- condyle.
 - coronoid.
 - facet.
 - tuberosity.

ANS: C

29. A term that means the same as *anterior* is:

- a. plantar.
- b. distal.
- c. dorsal.
- d. ventral.

ANS: D

30. The term that may also be used to refer to the posterior surface of the body is:
- a. dorsal.
 - b. ventral.
 - c. volar.
 - d. plantar.

ANS: A

31. The term that refers to parts away from the head of the body, or angling the central ray toward the feet is:
- a. caudad.
 - b. cephalad.
 - c. medial.
 - d. proximal.

ANS: A

32. The term that refers to parts nearer the point of attachment, or origin, is:
- a. distal.
 - b. proximal.
 - c. caudad.
 - d. cephalad.

ANS: B

33. The term used to describe the sole of the foot is:
- a. ventral.
 - b. posterior.
 - c. plantar.
 - d. dorsal.

ANS: C

34. A large, rounded, elevated process on a bone is called a(n):
- a. malleolus.
 - b. epicondyle.
 - c. tubercle.
 - d. tuberosity.

ANS: D

35. All of the following terms are used to describe “body positions,” *except*:
- a. upright.
 - b. axial.
 - c. prone.
 - d. LPO.

ANS: B

36. Which of the following is an x-ray “projection”?
- RPO
 - LAO
 - Dorsoplantar
 - Recumbent

ANS: C

37. Which of the following is an x-ray “position”?
- Mediolateral
 - Craniocaudal
 - Orbitoparietal
 - Trendelenburg

ANS: D

38. Which of the following is an x-ray “projection”?
- Tangential
 - Lordotic
 - Right anterior oblique (RAO)
 - Right lateral decubitus

ANS: A

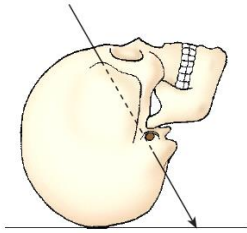
39. The path of the central ray stated as it exits the x-ray tube, travels through the patient and strikes the IR defines:
- radiography.
 - decubitus.
 - position.
 - projection.

ANS: D

40. If the central ray enters the anterior body surface and exits the posterior body surface, the x-ray projection is termed:
- PA.
 - AP.
 - lateral.
 - axiolateral.

ANS: B

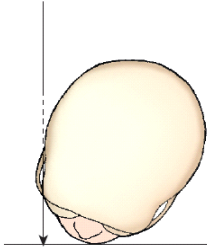
41. The x-ray projection identified in this figure is:



- a. AP.
- b. PA.
- c. AP axial.
- d. AP oblique.

ANS: C

42. Identify the x-ray projection illustrated in this figure.



- a. Tangential
- b. PA axial oblique.
- c. Orbitoparietal
- d. Parietoorbital

ANS: A

43. When there is longitudinal angulation of the central ray with the long axis of the body, the projection will always use the term:

- a. oblique.
- b. axial.
- c. lateral.
- d. decubitus.

ANS: B

44. Which of the following terms are used both as an x-ray projection and a body position?

- 1. Axial
 - 2. Oblique
 - 3. Lateral
- a. 1 and 2
 - b. 1 and 3
 - c. 2 and 3
 - d. 1, 2, and 3

ANS: C

45. The term used to describe the act of placing the patient appropriately for a radiographic examination is:

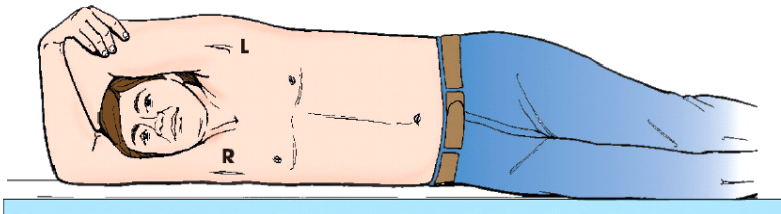
- a. supine.
- b. recumbent.
- c. projection.
- d. position.

ANS: D

46. Which of the following terms is used to describe a patient placed “lying on the back”?
- a. Supine
 - b. Prone
 - c. Lateral
 - d. Recumbent

ANS: A

47. What is the patient position illustrated in this figure?



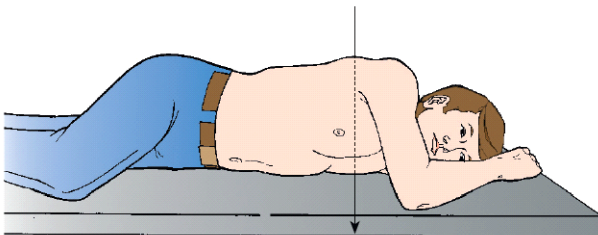
- a. Dorsal recumbent
- b. Right lateral recumbent
- c. Left lateral decubitus
- d. Trendelenburg

ANS: B

48. Oblique positions are always named according to the side of the patient that is:
- a. closest to the x-ray tube.
 - b. the source of pathology.
 - c. closest to the IR.
 - d. farthest from the IR.

ANS: C

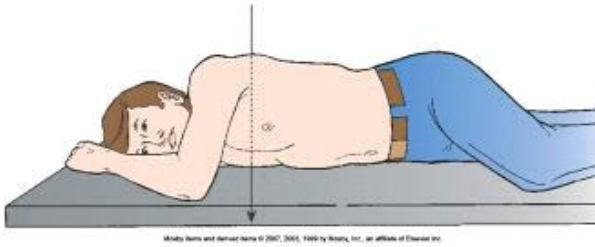
49. The patient in this figure is placed in which position?



- a. RPO
- b. LPO
- c. RAO
- d. LAO

ANS: D

50. The body position depicted below results in which x-ray projection?



- a. PA oblique
- b. AP oblique
- c. Recumbent
- d. Mediolateral

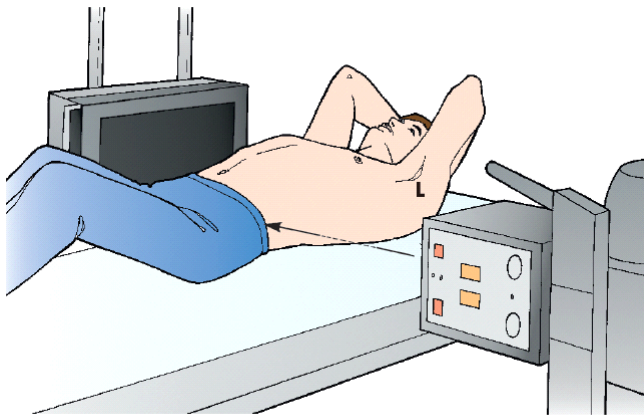
ANS: A

51. Which of the following positioning terms indicates that the patient is lying down and the central ray is horizontal?

- a. Lateral
- b. Decubitus
- c. Recumbent
- d. Mediolateral

ANS: B

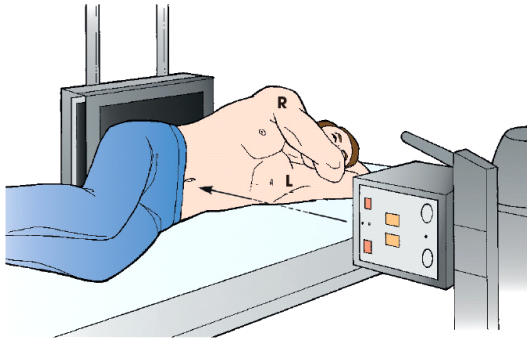
52. The patient in this figure is placed in which of the following positions?



- a. Left lateral decubitus
- b. Right lateral decubitus
- c. Dorsal decubitus
- d. Ventral decubitus

ANS: C

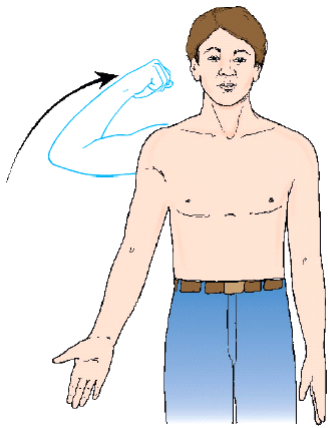
53. The x-ray projection shown in this figure is:



- a. AP.
- b. PA.
- c. right lateral.
- d. right lateral decubitus.

ANS: A

54. The movement shown in this figure is:



- a. adduction.
- b. abduction.
- c. extension.
- d. flexion.

ANS: D

55. Movement of a part away from the central axis of the body or body part is termed:

- a. adduction.
- b. abduction.
- c. extension.
- d. flexion.

ANS: B

56. Forced or excessive extension of a limb or part is termed:

- a. eversion.
- b. inversion.
- c. hyperextension.
- d. hyperflexion.

ANS: C

57. Rotation of the arm toward the midline of the body from the anatomic position is termed:
- pronation.
 - supination.
 - lateral rotation.
 - medial rotation.

ANS: D

58. If the foot is turned inward at the ankle joint, the body movement is termed:
- inversion.
 - eversion.
 - flexion.
 - extension.

ANS: A

59. Movement of a part toward the central axis of the body is termed:
- abduction.
 - adduction.
 - medial rotation.
 - lateral rotation.

ANS: B

60. Turning the forearm so that the palm of the hand is up is termed:
- pronation.
 - supination.
 - abduction.
 - adduction.

ANS: B

61. A club-shaped process on a bone is called a:
- coronoid.
 - trochanter.
 - tuberosity.
 - malleolus.

ANS: D

62. The term that refers to a part on the opposite side of the body is
- distal.
 - proximal.
 - ipsilateral.
 - contralateral.

ANS: D

63. Which of the following terms is plural?
- Calculi

- b. Labium
- c. Vertebra
- d. Bronchus

ANS: A

64. Study of the bones of the body is known as:
- a. physiology.
 - b. radiology.
 - c. osteology.
 - d. orthopedics.

ANS: C

65. Which of the following planes divides the body into superior or inferior portions?
- a. Horizontal
 - b. Oblique
 - c. Midsagittal
 - d. Midcoronal

ANS: A

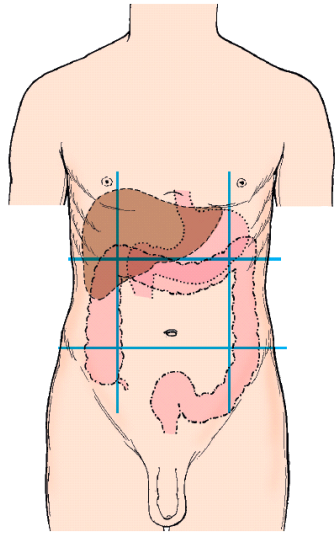
66. Which plane specifically divides the body into *equal* right and left halves?
- a. Axial
 - b. Transverse
 - c. Midcoronal
 - d. Midsagittal

ANS: D

67. The plane that divides the body into equal posterior and anterior halves is termed:
- a. horizontal.
 - b. longitudinal.
 - c. midcoronal.
 - d. midsagittal.

ANS: C

68. The upper, center region on this illustration is termed the:



- a. umbilical.
- b. epigastrium.
- c. hypogastrium.
- d. hypochondrium.

ANS: B

69. The vertebra prominens is located at the level of the:
- a. L2-L3.
 - b. L4-L5.
 - c. C3-C4.
 - d. C7-T1.

ANS: D

70. The jugular notch is located at the level of:
- a. T2-T3.
 - b. T4-T5.
 - c. L2-L3.
 - d. L4-L5.

ANS: A

71. For which type of body habitus will the lungs be very short and wide?
- a. Sthenic
 - b. Asthenic
 - c. Hypersthenic
 - d. Hyposthenic

ANS: C

72. For which type of body habitus will the stomach be the lowest?
- a. Sthenic
 - b. Asthenic
 - c. Hypersthenic
 - d. Hyposthenic

ANS: B

73. For which type of body habitus will the diaphragm be very high?
- Sthenic
 - Asthenic
 - Hyposthenic
 - Hypersthenic

ANS: D

74. The longest lungs will be found in which type of body habitus?
- Sthenic
 - Asthenic
 - Hyposthenic
 - Hypersthenic

ANS: B

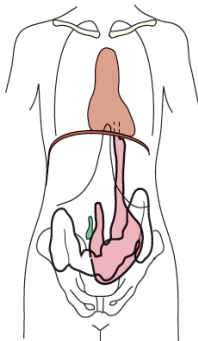
75. The lungs will be a moderate length in which body habitus?
- Sthenic
 - Asthenic
 - Hyposthenic
 - Hypersthenic

ANS: A

76. The stomach is positioned the highest in which type of body habitus?
- Sthenic
 - Asthenic
 - Hyposthenic
 - Hypersthenic

ANS: D

77. Which type of body habitus is shown in this illustration?



- Sthenic
- Asthenic
- Hyposthenic
- Hypersthenic

ANS: B

78. The appendicular skeleton allows the body to move in various positions. How many bones does it contain?
- 14
 - 80
 - 126
 - 206

ANS: C

79. Bones provide which of the following?
1. Protection of internal organs
 2. Production of red and white blood cells
 3. Attachment for the skin and fat layers
- 1 and 2
 - 1 and 3
 - 2 and 3
 - 1, 2, and 3

ANS: A

80. The red marrow within bones produces _____ cells.
1. adipose
 2. red blood
 3. white blood
- 1 and 2
 - 1 and 3
 - 2 and 3
 - 1, 2, and 3

ANS: C

81. What is the name of the tough, fibrous tissue that covers all bony surfaces?
- Endosteum
 - Periosteum
 - Compact bone
 - Spongy bone

ANS: B

82. The tissue lining the medullary cavity of bones is called the:
- endosteum.
 - periosteum.
 - trabeculae.
 - compact bone.

ANS: A

83. The part of the bone where muscles, tendons, or ligaments are attached is called:
- a foramina.
 - the meatus.
 - the fossa.

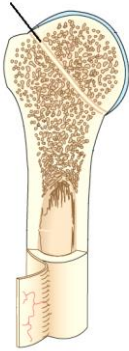
d. a tuberosity.

ANS: D

84. Near the center of all long bones is a specific opening in the periosteum called the:
- a. foramen.
 - b. nutrient foramen.
 - c. medullary cavity.
 - d. epiphyseal plate.

ANS: B

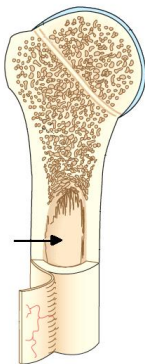
85. The area of the bone indicated by the line on this figure is the:



- a. periosteum.
- b. endosteum.
- c. compact bone.
- d. epiphyseal line.

ANS: D

86. The area of the bone indicated by the arrow on this figure is the:



- a. spongy bone.
- b. compact bone.
- c. medullary cavity.
- d. medullary cavity.

ANS: C

87. The piece of cartilage that separates the end of a developing long bone from the central shaft is called the:
- a. diaphysis.

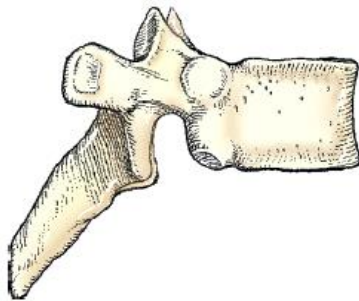
- b. epiphysis.
- c. epiphyseal line.
- d. epiphyseal plate.

ANS: D

88. Near the age of 21, full ossification occurs between the ends and the central shaft of long bones. The moderately visible area where the bones join is called the:
- a. epiphyseal line.
 - b. epiphyseal plate.
 - c. primary center of ossification.
 - d. secondary center of ossification.

ANS: A

89. What is the classification of the bone shown in this illustration?



- a. Long
- b. Short
- c. Irregular
- d. Sesamoid

ANS: C

90. The study of joints or articulations is known as:
- a. arthrology.
 - b. osteology.
 - c. radiology.
 - d. radiography.

ANS: A

91. How many specific types of joints are contained within the structural classification of joints?
- a. 3
 - b. 4
 - c. 6
 - d. 11

ANS: D

92. The syndesmosis, suture, and gomphosis joints belong to which structural joint group?
- a. Hinge joints
 - b. Fibrous joints
 - c. Synovial joints

d. Cartilaginous joints

ANS: B

93. Which structural joint group contains joints that are all freely movable?
- a. Hinge joints
 - b. Fibrous joints
 - c. Synovial joints
 - d. Cartilaginous joints

ANS: C

94. Which specific type of joint permits only flexion and extension?
- a. Hinge joints
 - b. Gliding joints
 - c. Pivot joints
 - d. Saddle joints

ANS: A

95. The small, rounded, elevated process on a bone is called a(n):
- a. malleolus.
 - b. tubercle.
 - c. epicondyle.
 - d. protuberance.

ANS: B

96. A tubelike passageway running within a bone is called a:
- a. fossa.
 - b. groove.
 - c. meatus.
 - d. foramen.

ANS: C

97. Which of the following terms refers to the covering of an organ?
- a. External
 - b. Internal
 - c. Visceral
 - d. Parietal

ANS: C

98. Which of the following terms refers to the back part of a body or organ?
- a. Ventral
 - b. Dorsal
 - c. Distal
 - d. Proximal

ANS: B

99. Reference toward the head of the body is termed:

- a. external.
- b. proximal.
- c. caudad.
- d. cephalad.

ANS: D

100. The term that refers to parts *farthest* from the point of attachment, point of reference, or away from the center of the body is:
- a. distal.
 - b. proximal.
 - c. caudad.
 - d. cephalad.

ANS: A

101. A serious fracture in which the broken bone or bones project through the skin is called a(n) _____ fracture.
- a. open
 - b. closed
 - c. displaced
 - d. nondisplaced

ANS: A

102. A serious fracture in which the bones are not in anatomic alignment is called:
- a. impacted.
 - b. compression.
 - c. displaced.
 - d. nondisplaced.

ANS: C

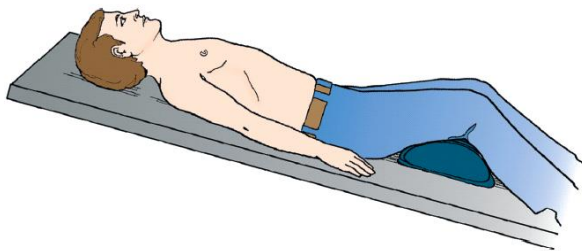
103. When a fractured bone retains its normal alignment, it is called:
- a. greenstick.
 - b. compound.
 - c. displaced.
 - d. nondisplaced.

ANS: D

104. When a fractured bone is shattered into many pieces, it is called:
- a. spiral.
 - b. transverse.
 - c. compression.
 - d. comminuted.

ANS: D

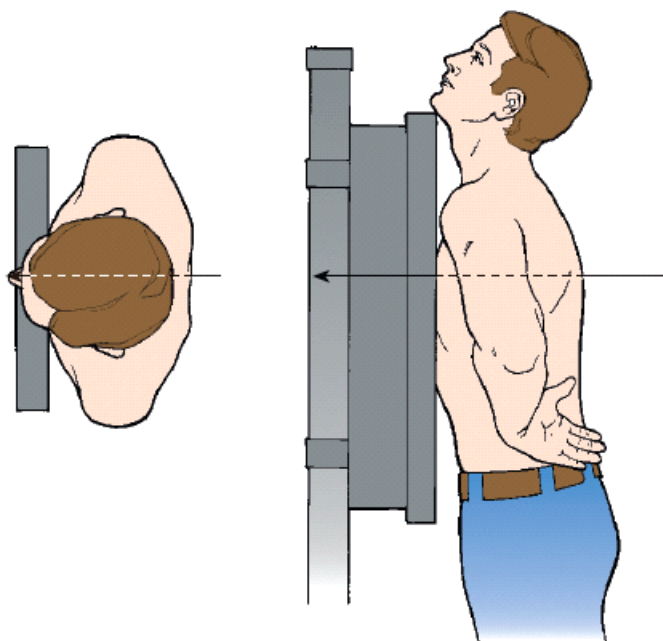
105. The body position in this illustration is:



- a. prone.
- b. Fowler.
- c. Trendelenburg.
- d. anteroposterior.

ANS: B

106. The projection shown in this illustration is:



- a. AP.
- b. PA.
- c. AP axial.
- d. PA axial.

ANS: B

107. Movement or positioning of the hand toward the radius or ulna is termed:

- a. abduction.
- b. eversion.
- c. supination.
- d. deviation.

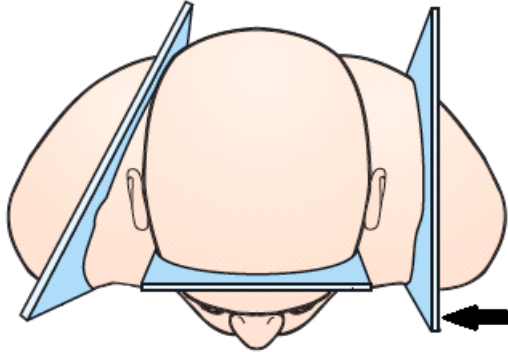
ANS: D

108. Tipping or slanting a body part slightly is termed:

- a. extension.
- b. eversion.
- c. tilting.
- d. oblique.

ANS: C

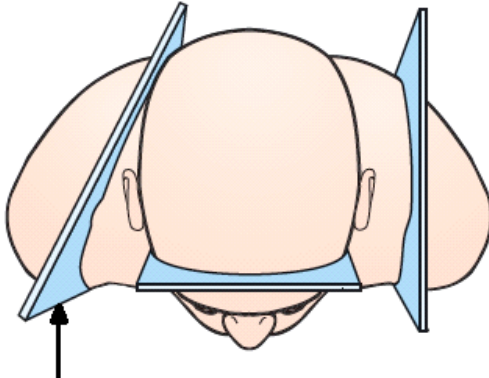
109. The plane indicated by the arrow in this figure is the:



- a. sagittal.
- b. coronal.
- c. oblique.
- d. horizontal.

ANS: A

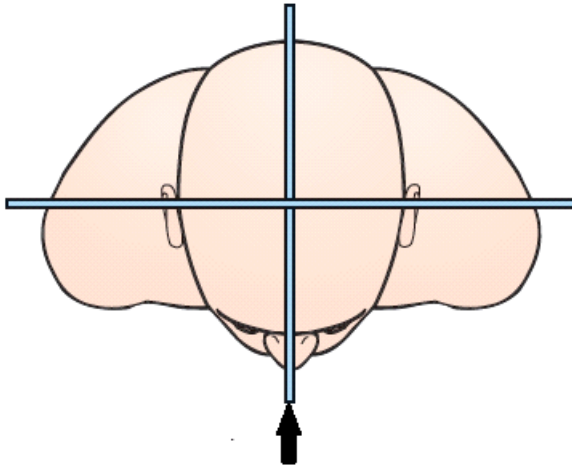
110. The plane indicated by the arrow in this figure is the:



- a. sagittal.
- b. coronal.
- c. oblique.
- d. horizontal.

ANS: C

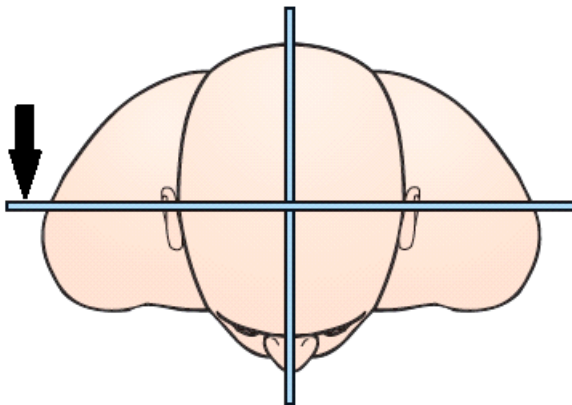
111. The body plane indicated by the arrow in this figure is the:



- a. midcoronal.
- b. midsagittal.
- c. horizontal.
- d. transverse.

ANS: B

112. The body plane indicated by the arrow in this figure is the:



- a. sagittal.
- b. coronal.
- c. midsagittal.
- d. midcoronal.

ANS: D

113. When the hand is turned toward the radial side, it is termed:

- a. radial deviation.
- b. ulnar deviation.
- c. abduction.
- d. adduction.

ANS: A

114. When the hand is turned toward the ulnar side, it is termed:

- a. adduction.
- b. abduction.
- c. ulnar deviation.
- d. radial deviation.

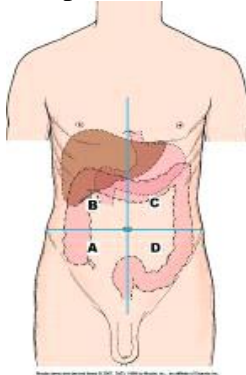
ANS: C

115. The largest sesamoid bone in the body is the:

- a. atlas.
- b. axis.
- c. patella.
- d. flabella.

ANS: C

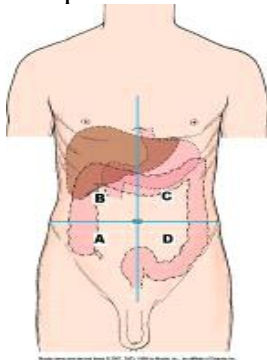
116. The portion of the abdominal cavity labeled as *D* in this figure is the _____ quadrant.



- a. right upper
- b. left upper
- c. right lower
- d. left lower

ANS: D

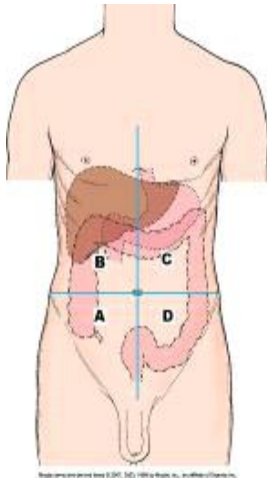
117. The portion of the abdominal cavity labeled as *B* in this figure is the _____ quadrant.



- a. right upper
- b. left upper
- c. right lower
- d. left lower

ANS: A

118. The portion of the abdominal cavity labeled as *C* in this figure is the _____ quadrant.



- a. right upper
- b. left upper
- c. right lower
- d. left lower

ANS: B

119. In which quadrant of the abdomen is the appendix usually located?
- a. RUQ
 - b. RLQ
 - c. LUQ
 - d. LLQ

ANS: B

120. The vertebrae located at approximately the same level as the xiphoid process are:
- a. C7-T1.
 - b. T1-T2.
 - c. T9-T10.
 - d. L2-L3.

ANS: C

121. Which structure can be palpated by an imaging professional palpate to locate the level of the pubic symphysis?
- a. Coccyx
 - b. ASIS
 - c. Iliac crest
 - d. Greater trochanter

ANS: D

122. Which bone classification is defined as those that develop in or near tendons?
- a. Sesamoid
 - b. Irregular
 - c. Short
 - d. Flat

ANS: A

MULTIPLE RESPONSE

1. Which two of the following lie in the pelvic cavity? (*Select all that apply.*)
 - a. Kidneys
 - b. Rectum
 - c. Urinary bladder
 - d. Pancreas

ANS: B, C

2. Which two terms are used to describe x-ray “projections”? (*Select all that apply.*)
 - a. AP
 - b. PA axial
 - c. Supine
 - d. RPO

ANS: A, B