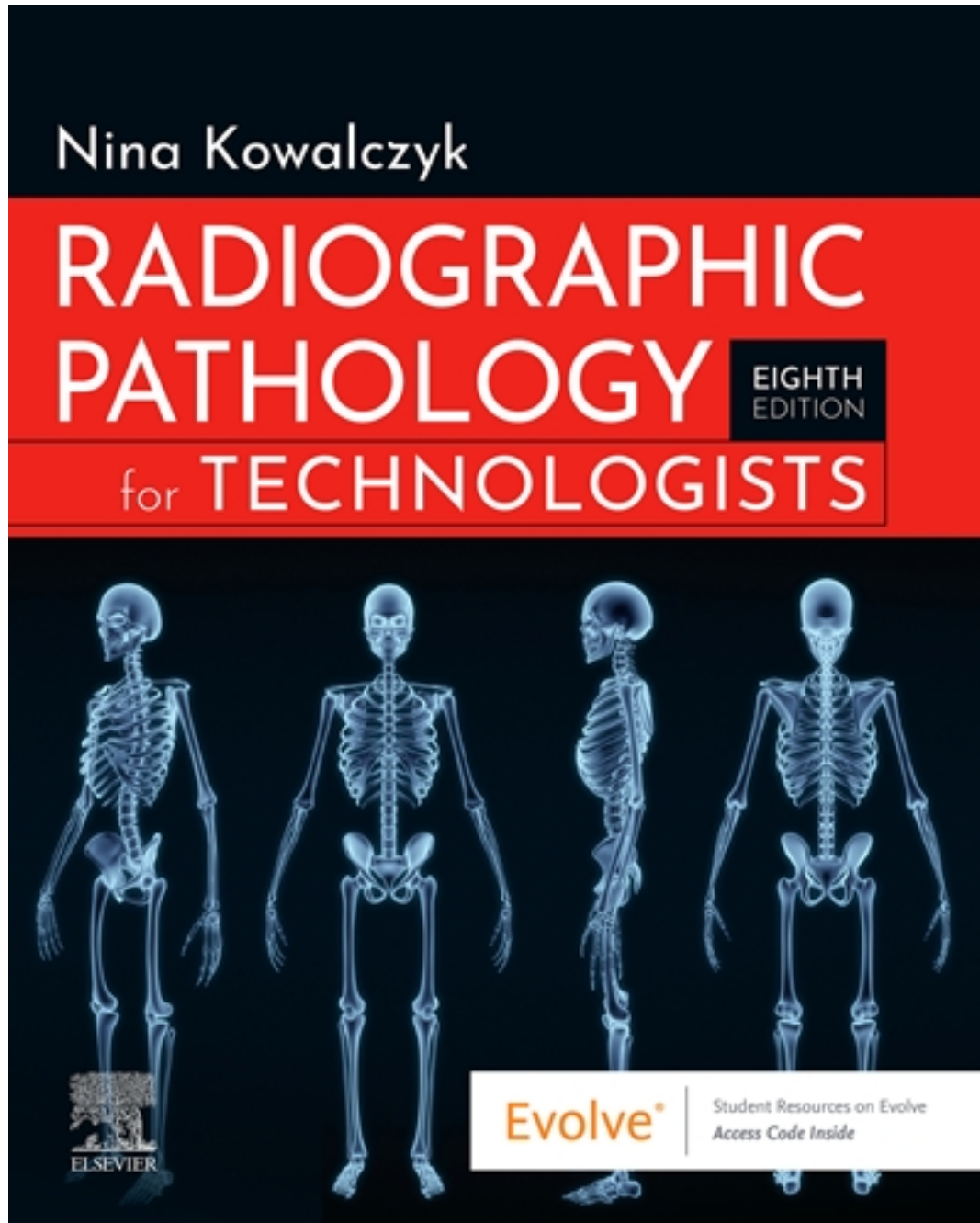


Test Bank for Radiographic Pathology for Technologists 8th Edition by Kowalczyk

[CLICK HERE TO ACCESS COMPLETE Test Bank](#)



Test Bank

Chapter 02: Skeletal System

Kowalczyk: Radiographic Pathology for Technologists, 8th Edition

MULTIPLE CHOICE

1. Which primary bone tumor should be investigated with the utilization of CT?
 - a. Osteosarcoma
 - b. Osteoid osteoma
 - c. Chondrosarcoma
 - d. Ewing sarcoma

ANS: B

2. Which of the following characteristics does NOT assist in the differentiation between a primary metastatic bone lesion as compared to a secondary metastatic bone lesion?
 - a. Soft tissue mass
 - b. Periosteal reaction
 - c. Length of lesion
 - d. Calcification of blood vessels

ANS: D

3. What skeletal pathology presents radiographically with a “soap bubble” appearance?
 - a. Giant cell tumor
 - b. Ewing sarcoma
 - c. Osteoid osteoma
 - d. Osteoblastoma

ANS: A

4. Osteopetrosis requires what type of technical factor change?
 - a. Increase
 - b. Decrease
 - c. No change

ANS: A

5. Which neoplasm involves a nidus?
 - a. Osteoid osteoma
 - b. Osteoblastoma
 - c. Osteosarcoma
 - d. Paget disease

ANS: A

6. Which disease is congenital?
 - a. Pott disease
 - b. Osteoporosis
 - c. Paget disease
 - d. Osteogenesis imperfecta

ANS: D

7. Diploë is specific to cancellous bone located in what anatomic structure?
- a. Femur
 - b. Humerus
 - c. Sternum
 - d. Skull

ANS: D

8. A 15-year-old male patient presents for a right knee series after sustaining a varus injury while playing football. AP, lateral, and both oblique radiographs of the knee demonstrate an avulsion fracture of the lateral tibial plateau (Segond fracture). What additional imaging modality would be best utilized in the diagnosis for this patient?
- a. CT
 - b. Knee arthrography
 - c. MRI
 - d. Nuclear medicine

ANS: C

9. Heberden nodes and Bouchard nodes are associated with what skeletal pathology?
- a. Osteomyelitis
 - b. Osteoarthritis
 - c. Paget disease
 - d. Pott disease

ANS: B

10. What skeletal pathology could be a contributing factor for a cervical rib?
- a. Scoliosis
 - b. Spina bifida
 - c. Spondylolisthesis
 - d. Transitional vertebrae

ANS: D

11. Which anatomic structure is NOT a common area for metastasis?
- a. Pelvis
 - b. Carpals
 - c. Skull
 - d. Bony thorax

ANS: B

12. "Brittle bone" disease is also known as
- a. achondroplasia.
 - b. DDH.
 - c. osteogenesis imperfecta.
 - d. osteopetrosis.

ANS: C

13. Congenital clubfoot is also known as

- a. DDH.
- b. syndactyly.
- c. fibrous dysplasia.
- d. talipes.

ANS: D

14. The most common form of arthritis is
- a. osteoarthritis.
 - b. gouty arthritis.
 - c. psoriatic arthritis.
 - d. rheumatoid arthritis.

ANS: A

15. Marie–Strümpell disease or “bamboo spine” is a symptom of the pathology known as
- a. ankylosing spondylitis.
 - b. spondylolisthesis.
 - c. spina bifida.
 - d. scoliosis.

ANS: A

16. What type of arthritis has tophi associated with it?
- a. Osteoarthritis
 - b. Gouty arthritis
 - c. Psoriatic arthritis
 - d. Rheumatoid arthritis

ANS: B

17. What imaging modality demonstrates both simultaneous evaluation of bone and soft tissues with quantitative metabolic data of osteosarcomas?
- a. CT
 - b. Nuclear medicine bone scan
 - c. Sonography
 - d. PET scan

ANS: D

18. Tuberculosis of the spine is commonly referred to as
- a. Kienbock disease.
 - b. Reiter syndrome.
 - c. Apert syndrome.
 - d. Pott disease.

ANS: D

19. The imaging modality that would best demonstrate osteomyelitis is
- a. nuclear medicine.
 - b. radiography.
 - c. CT.
 - d. sonography.

ANS: A

20. One of the most common areas for metastasis for osteosarcomas is to the
- brain.
 - breast.
 - lung.
 - colon.

ANS: C

21. A 30-year-old male presents with swelling and redness on his left knee. He states that he lays carpet and rarely wears knee pads. The orthopedic surgeon decides to aspirate the swollen area and inject it with a corticosteroid. What would be the differential diagnosis?
- Calcific tendinitis
 - Tenosynovitis
 - Ganglion cyst
 - Prepatellar bursitis

ANS: D

22. A malignant tumor composed of atypical cartilage is known as
- chondrosarcoma.
 - osteosarcoma.
 - enchondroma.
 - osteoid osteoma.

ANS: A

23. What skeletal pathology involves cysts in the metaphysis of long bones in individuals younger than 20 years of age and consists of numerous blood-filled arteriovenous communications?
- Unicameral bone cyst
 - Aneurysmal bone cyst
 - Ganglion cyst
 - Osteoid osteoma

ANS: B

24. What type of aggressive bone-forming neoplasm that is most often located in the bone marrow gives the radiographic appearance of a sunray or sunburst?
- Osteomyelitis
 - Osteosarcoma
 - Chondrosarcoma
 - Multiple myeloma

ANS: B

25. Which syndrome may involve craniosynostosis and syndactyly?
- Pott syndrome
 - Reiter syndrome
 - Kienbock syndrome
 - Apert syndrome

ANS: D

26. Which of the following congenital skeletal pathologies involves failure of formation of the cranial vault and is not conducive for life?
- a. Anencephaly
 - b. Craniosynostosis
 - c. Encephalopathy
 - d. Osteomyelitis

ANS: A

27. A nuclear medicine bone scan is performed for a diagnosis of osteomyelitis of the right foot. If this procedure is positive, what would the images demonstrate?
- a. Symmetry of both feet
 - b. Increased uptake on the right foot (hot spot)
 - c. Decreased uptake on the right foot (cold spot)

ANS: C

28. The most commonly inherited disorder affecting the skeletal system is
- a. enchondroma.
 - b. osteogenesis imperfecta.
 - c. achondroplasia.
 - d. syndactyly.

ANS: C

29. A 65-year-old female presents with bilateral knee pain and no history of injury. What radiographic procedure should be obtained initially?
- a. Bilateral weight-bearing knee radiographs
 - b. CT of both knees
 - c. Arthrography of both knees
 - d. MRI of both knees

ANS: A

30. A 75-year-old patient with weight-bearing AP and lateral knee radiographs of the left knee demonstrates a decreased medial joint compartment and osteophyte formation on the medial femoral condyle. What would be the initial diagnosis?
- a. Ewing sarcoma
 - b. Osteoarthritis
 - c. Reiter syndrome
 - d. Osteomyelitis

ANS: B

31. The primary site of ossification is the
- a. epiphysis.
 - b. metaphysis.
 - c. diaphysis.
 - d. epiphyseal plate.

ANS: C

TRUE/FALSE

1. The staging systems used for both benign and malignant skeletal lesions are identical.

ANS: T