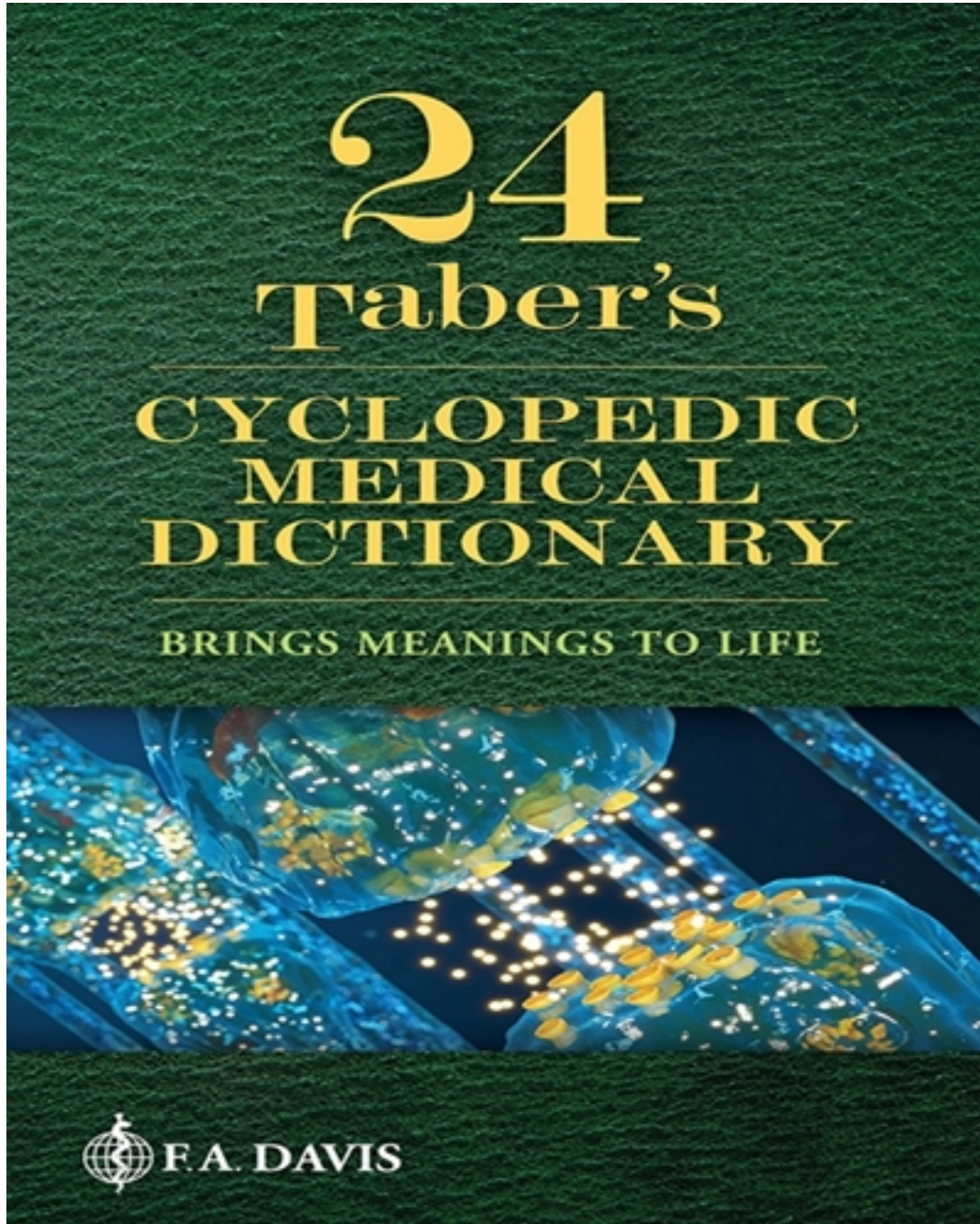


# Test Bank for Taber's Cyclopedic Medical Dictionary 3rd Edition by Venes

[CLICK HERE TO ACCESS COMPLETE Test Bank](#)



# Test Bank

## Anatomy- Muscles

### Multiple Choice

Identify the choice that best completes the statement or answers the question.

- \_\_\_\_ 1. The extraocular muscles control:
- A The movements of the eyes
  - B The movements of all the facial muscles, except those of the eyes
  - C The movements of the arms
  - D The body's sphincters
- \_\_\_\_ 2. The masseter muscles are involved in:
- A Squinting
  - B Sniffing
  - C Chewing
  - D Grasping
- \_\_\_\_ 3. Failure of the muscles of the eyelids to stay fully open, resulting in a partly closed eye is known as:
- A Miosis
  - B Anhydrosis
  - C Ptosis
  - D Mydriasis
- \_\_\_\_ 4. The lingual muscle is used to:
- A Speak
  - B Chew
  - C Swallow
  - D All of the above
  - E None of the above
- \_\_\_\_ 5. Effacement of the nasolabial fold is found in:
- A Encephalitis
  - B Writer's cramp
  - C Trigger finger
  - D Bell's palsy
- \_\_\_\_ 6. Flexion of the elbow primarily involves contraction of which of the following muscles?
- A The triceps
  - B The biceps
  - C The pectoralis major
  - D The pectoralis minor
- \_\_\_\_ 7. You patient has his foot placed flat on the ground. You ask him to draw his toes up off the ground, a movement known technically as:
- A Plantar flexion
  - B Dorsiflexion
  - C Involuntary movement
  - D Involuntary spasm
- \_\_\_\_ 8. You ask your patient to lie upon her back, then to bend her right knee up so that she can place her right heel on her LEFT kneecap (on the patella). You place your hand on the medial side of her RIGHT knee, and push the lateral side of the knee toward the examination table. This maneuver:
- A Externally rotates the hip joint
  - B Internally rotates the hip joint
  - C Flexes the hip joint
  - D Extends the hip joint
- \_\_\_\_ 9. Which of the following muscles is most powerfully used during jumping up from a standing position?
- A Serratus
  - B Soleus
  - C Trapezius
  - D Pectoralis minor
- \_\_\_\_ 10. Which of the following muscles is not found in the lower extremity?
- A Flexor carpi radialis
  - B Gastrocnemius
  - C Vastus medialis
  - D Semitendinosus

## **Anatomy- Muscles Answer Section**

### **MULTIPLE CHOICE**

1. ANS: A

The extraocular muscles control eye movements. They include the medial and lateral rectus muscles, the superior and inferior rectus muscles, and the superior and inferior oblique muscles.

PTS: 1

2. ANS: C

The masseter muscles are primarily used in chewing. Extraocular and facial muscles are used to squint and sniff. Grasping is performed by the intrinsic muscles of the hands.

PTS: 1

3. ANS: C

Drooping of the eyelids is a condition known as ptosis. It is a common finding in several diseases, including, for example, myasthenia gravis.

PTS: 1

4. ANS: D

The lingual muscle (also known as the tongue) is used to speak, chew, and swallow.

PTS: 1

5. ANS: D

Weakness of facial muscles often results in loss of facial definition, such as effacement of the nasolabial fold. This is a common finding in Bell's palsy, a peripheral nerve palsy that paralyzes one half of the face.

PTS: 1

6. ANS: B

The elbow flexes when the biceps muscle of the arm contracts. The triceps muscle extends the elbow. The pectoralis major and minor muscles are muscles of the chest wall.

PTS: 1

7. ANS: B

The voluntary elevation of the toes off the floor (or "toward the nose") is called dorsiflexion. Plantar flexion of the toes is performed by curling or flexing the toes toward the floor.

PTS: 1

8. ANS: A

External rotation of the hip is any movement in which the hip joint turns away from the body's midline. Internal hip rotation involves movement of the joint toward the midline. Flexion of the hip is performed by bringing the knee toward the chest. The hip extends when the leg is drawn backward (away from the body's anterior surface).

PTS: 1

9. ANS: B

The soleus, one of the deep muscles of the calf, is used during jumping. The trapezius is a muscle that links the upper back, neck and shoulders. The serratus muscles are found on the trunk. The pectoralis minor muscle is a muscle of the chest.

PTS: 1

10. ANS: A

The flexor carpi radialis, as the name implies is a muscle on the radial side of the wrist (in Latin, the “carpus”). The other listed muscles are found in the leg.

PTS: 1